

# Clinical crown length changes from age 12–19 years: a longitudinal study

L.A. Morrow<sup>a,\*</sup>, J.W. Robbins<sup>b</sup>, D.L. Jones<sup>c</sup>, N.H.F. Wilson<sup>a</sup>

<sup>a</sup>Restorative Dentistry, University Dental Hospital of Manchester, Higher Cambridge Street, Manchester M15 6FH, UK

<sup>b</sup>Department of General Dentistry, University of Texas, Health Science Center at San Antonio, San Antonio, TX, USA

<sup>c</sup>Department of Community Dentistry, University of Texas Health Science Center at San Antonio, San Antonio, TX, USA

Received 25 October 1999; received in revised form 6 December 1999; accepted 16 February 2000

## Abstract

**Objective:** The objective of this study was to investigate the relationship between age, gender and clinical crown length using a longitudinal study design.

**Method:** Four hundred and fifty-six sets of study models initially obtained for a large prospective longitudinal cohort study of orthodontic needs were examined. Each set of models corresponded to subjects at three different ages: 11–12, 14–15 and 18–19 years old. The clinical crown height of the maxillary right central incisor (11), maxillary right canine (13), maxillary left lateral incisor (22) and mandibular left central incisor (31) was measured from gingival crest to the incisal edge using digital calipers.

**Results:** Analysis revealed a significant ( $p < 0.0001$ ) age effect on crown length for all four teeth investigated. A significant gender effect was found in relation to the maxillary right canine, maxillary right central incisor and maxillary left lateral incisor. Pairwise comparisons of the means for each age group for the maxillary right canine, maxillary right central incisor and maxillary left lateral incisor revealed significant ( $p < 0.0001$ ) increases in clinical crown length between each assessment period.

**Conclusion:** The findings of the present study indicate that, the process of passive eruption, resulting in increased clinical crown length appears to continue throughout the teenage years. This finding is considered to be of importance to the clinician making treatment decisions for teenagers and young adults requiring treatment in the anterior segments of the mouth. © 2000 Elsevier Science Ltd. All rights reserved.

**Keywords:** Clinical crown length; Eruption (active, passive); Longitudinal study

## 1. Introduction

With increased emphasis on dental aesthetics, there has been a concomitant increase in the interest in the periodontal-restorative interface [1,2]. It is widely acknowledged that the gingival tissues surrounding the teeth have a significant impact on the overall aesthetic presentation [3,4]. Therefore, an understanding of the factors that affect the position and stability of the gingival complex is essential if the dentist is to provide predictable, long-term aesthetic restorative therapy.

One of the initial steps in diagnosing a smile is to evaluate the clinical crown length of the maxillary central incisors. Clinical crown length plays a significant role in the functional aesthetic display, not only during a full smile, but also during speaking and even in repose [5–7]. The ultimate length of the clinical crown of an anterior tooth is dependent upon several factors. These include genetic and develop-

mental factors, incisal edge wear, active and passive eruption.

Developmentally, the average length of the fully erupted maxillary central incisor in the adult patient is 9.5–11 mm [8]. Central incisors of shorter length do occur; however, the teeth are proportionally narrower so that the width is 75–80% of the height of the tooth. Rarely are short wide central incisors, with a height/width ratio of less than 1:1 observed clinically. Clinical crowns may appear short due to incisal edge wear; however, the aetiology may be diagnosed by observing the increased incisal edge width due to the wear process.

The maxillary central incisor erupts into the mouth at approximately six years of age and continues to erupt until it comes into contact with the opposing teeth. This process is termed active eruption. At this point, approximately 50% of the anatomic crown is covered with gingivae. Over the next several years, the gingiva slowly migrate up the labial surface of the anatomic crown until it stabilises approximately 1–2 mm from the cemento–enamel junction (CEJ). This is termed passive eruption [9]. In a small percentage of patients, the tissue does not migrate far

\* Corresponding author. Tel.: + 44-161-275-6660; fax: + 44-161-275-6710.

E-mail address: leean.morrow@man.ac.uk (L.A. Morrow).

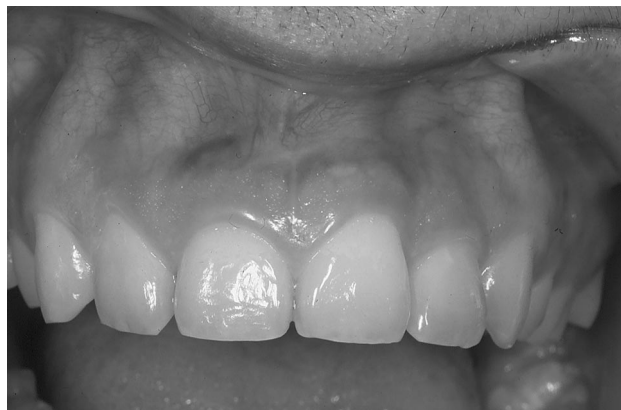

Fig. 1. View of upper anterior segment, showing an upper right central incisor with a short clinical crown due to excess gingival coverage of the anatomic crown, (“altered passive eruption” or “delayed passive eruption”).

enough apically to approximate the CEJ. This ultimately results in short clinical crowns due to excess gingival coverage of the anatomic crown (Fig. 1). This condition is termed “altered passive eruption” or “delayed passive eruption” [10–12].

There are currently many modalities available for improving the presentation of a smile. These include bleaching, direct bonded composite, indirect veneers and crowns, gingival recontouring, orthodontics, and orthognathic surgery [13–17]. It is no surprise that these treatment modalities have been embraced with the same enthusiasm by teenagers as they have by adults. However, teenagers are more problematic because their stomatognathic systems have not stabilised [18]. Tissue migration, i.e. passive eruption, as well as growth are ongoing during these years. Diagnosing a system, which is in a state of flux is like trying to hit a moving target. For this reason, many practitioners choose to use only reversible procedures on teenage patients because of the risk of continued apical migration of the gingival tissues. Volchansky and Cleaton-Jones [18] investigated the effect of age on clinical crown height in a cross sectional study. They measured the lengths of the clinical crowns on 237 pretreatment orthodontic study casts of

children aged 6–16 years. In the mandibular arch, there was no statistically significant increase in the clinical crown height after the age of 10 years in the central incisors, or after the age of 12 years in the canines. The clinical height of the lateral incisors however, did continue to show a significant increase through until the age of 16 years. The results were similar for the maxillary teeth. There was no statistically significant increase in the clinical crown height of the central incisors and the canines after the age of 12 years. However, there was a significant increase in the length of the lateral incisors through to age 16 years.

The present study was undertaken to investigate the relationship between age, gender and clinical crown length using a longitudinal study design.

## 2. Materials and methods

In a large prospective longitudinal cohort study of orthodontic needs, Shaw et al. [19] selected a group of 1018 Welsh children between 11 and 12 years of age. Initially, criteria developed to identify various occlusal conditions were applied to the available population of 3420 children. Each occlusion was classified according to the first applicable category, which included deep overbite, prominent incisors, partial anterior crossbite, total anterior crossbite, general anterior spacing, midline spacing, missing incisors, exposed maxillary gingival and severe anterior crowding. The remainder, were recorded as ‘non-specific’. The final allocation of subjects to the study was determined by disproportionate stratified sampling to ensure that occlusal condition of low prevalence but high orthodontic interest would be well represented in the cohort. Based on a dental examination, half of the children with severe anterior crowding ( $n = 173$ ) and half of the children with exposed maxillary gingivae ( $n = 38$ ) were randomly selected. Exposed maxillary gingivae was defined as any part of the maxillary gingivae (including the papilla) being visible while the lips were at rest. In addition, all children with occlusions in the remaining specific categories were included. This selection process produced a total of 663 children, approximately 20% of those children initially screened (Table 1). Ten percent of the children with non-specific occlusal arrangements were included ( $n = 355$ ), giving a total of 1018 subjects. As part of this investigation, study casts were made of each participant from alginate impressions. The first examination was carried out at age 11–12 years. Subsequently, study casts were made three years later (age 14–15 years) and again four years later (age 18–19 years). It is these study casts, along with gender records, that were used to longitudinally evaluate the relationship between age, gender and clinical crown length in the present study.

The maxillary right central incisor (11), maxillary right canine (13), maxillary left lateral incisor (22) and

Table 1  
Occlusal conditions of the children initially allocated to the study

Occlusal condition	Number ( $n$ )	Percentage (%)
Deep overbite	65	6.4
Prominent incisors	80	7.8
Partial anterior crossbite	163	16.0
Total anterior crossbite	23	2.2
General anterior spacing	36	3.5
Midline space	12	1.2
Missing incisor	73	7.2
Exposed maxillary gingival	38	3.7
Severe anterior crowding	173	17.0
Non-specific	355	34.9
Total	1018	100.0

Table 2  
Mean clinical crown length (mm) according to age and gender for each of the three examination ages

Tooth	11–12 years			14–15 years			18–19 years		
	Male	Female	Mean	Male	Female	Mean	Male	Female	Mean
11	9.23	9.00	9.11	9.56	9.36	9.46	10.13	9.79	9.96
13	7.69	7.49	7.58	8.99	8.61	8.77	9.54	9.06	9.27
22	7.23	7.03	7.13	7.83	7.65	7.73	8.39	8.15	8.27
31	7.76	7.80	7.78	7.84	7.98	7.92	8.23	8.20	8.22

mandibular left central incisor (31) were selected for inclusion in the study. The clinical crown height was measured from gingival crest to the incisal edge for each study tooth at the three different examination ages. The same investigator made all tooth measurements using a digital calliper to an accuracy of 0.005 mm. The investigator performed all the assessments on three separate occasions, with seven days between each assessment. When there was an inconsistency between the three scoring, the most frequent score was recorded. Where there was a wide disparity the mean score was used. Those teeth with visible intra-coronal or extra-coronal restorations, impression/casting inaccuracies or fixed orthodontic appliances were excluded from the study, as these factors prevented the accurate measuring of the clinical crown height. This selection technique therefore excluded those cases who were actively undergoing fixed orthodontic at the time of examination and impression taking. Only those samples, which contained all three exam-

ination period study casts were included in the study. This resulted in a total of 456 sets of study models being available for examination and inclusion in the present study.

The results were tabulated and the mean clinical crown length according to age and gender for each of the three examination periods were calculated. The data were analysed using a factorial analysis of variance design with two factors, age and gender. Pairwise comparisons were made using the Scheffe S method. The level of significance for all comparisons was set at  $p < 0.05$ .

### 3. Results

Analysis of the data obtained revealed a significant ( $p < 0.0001$ ) age effect on crown length for all four study teeth. A significant gender effect was found in the maxillary right central incisor, maxillary right canine and maxillary left

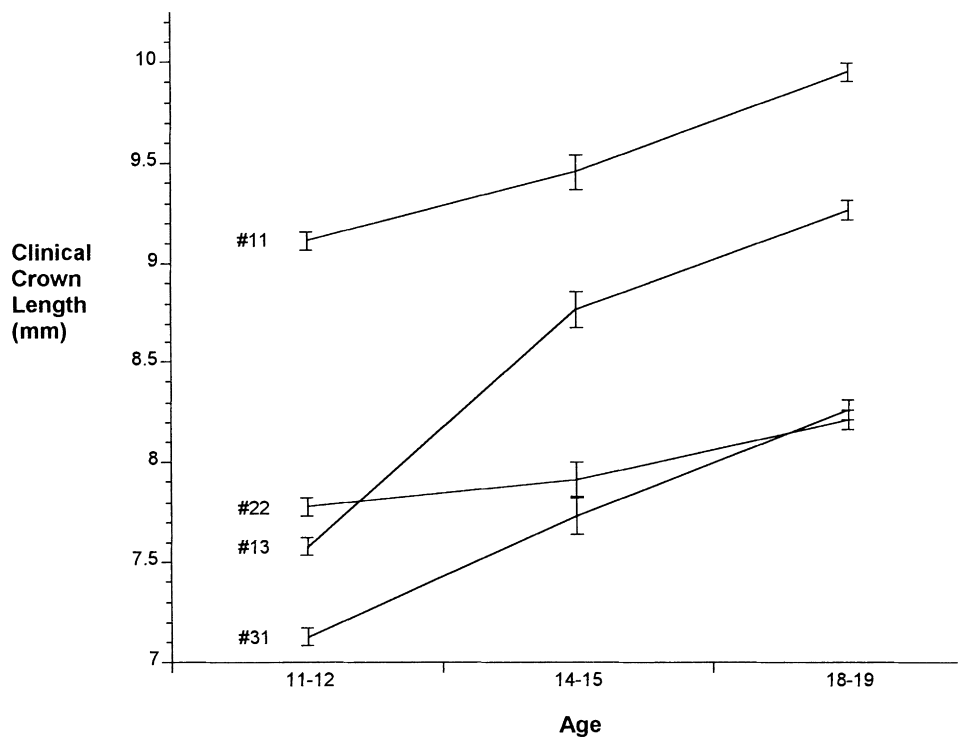


Fig. 2. The effect of age on the clinical crown length of the teeth investigated. #11 maxillary right central incisor, #13 maxillary right canine, #22 maxillary left lateral incisor and #31 mandibular left central incisor.

Table 3  
Average crown lengths (mm) as reported by Gillen et al. [8]

Tooth	Male	Female
11	10.55	9.53
13	10.67	9.23
22	9.10	8.20

lateral incisor (11,13,22). There was no statistically significant gender effect for the mandibular left central incisor (31). However, there was a significant age and gender interaction effect which was not found in the other study teeth. The mean clinical crown length for each age and gender group is listed in Table 2. Pairwise comparisons of the means for each age group for the maxillary right central incisor (11), maxillary right canine (13) and maxillary left lateral incisor (22) and tests of simple main effects for the mandibular left central incisor (31) revealed significant ( $p < 0.0001$ ) increases in clinical crown length at each assessment period. The age effect on crown length for each of the teeth studied is depicted graphically in Fig. 2.

#### 4. Discussion

The results of this study are not in agreement with those reported by Volchansky and Cleaton-Jones [18]. These workers found that the length of the mandibular central incisor stabilised by age 10 years and the length of the maxillary central incisor and canines by age 12 years. The data in this study indicates that passive eruption continues at least until age 18–19 years in the maxillary central incisors, lateral incisors, canines, and mandibular central incisors for both males and females.

This finding is considered to be of considerable clinical importance since the instability of the position of the gingival crest in teenagers may affect the type of restorative treatment offered to such patients concerned about their dental attractiveness. From the data it is not possible to determine whether or not the gingival levels are actually stable at age 18–19 years. Based on a comparison of the clinical crown lengths reported in this study with those reported by Gillen et al. [8] (Table 3), it appears that in the female patient population in the present study, passive eruption is essentially complete by age 18–19 years. In contrast, in the male patient population, it appears that passive eruption may not be complete at age 18–19 years. The results revealed that there was a 0.5 mm change in the clinical length of the maxillary incisors and canine between the ages of 14–15 and 18–19 years. The clinical significance of this change in crown length, despite the small magnitude, could have a detrimental effect on the marginal aesthetics of definitive indirect restorations placed in the anterior segment of the mouth between these age bands. It could therefore be suggested that definitive restorative treatment such as porcelain veneers and crowns should possibly be delayed until after 19 years of age.

It is possible that incisal edge wear, the presence of restorations, effects of orthodontic intervention and gingival swelling due to poor oral hygiene and inflammation could have resulted in altered clinical crown lengths. However, based on the observations of the investigator who measured the casts, none of these factors was perceived to have had a significant effect on the findings. Casts with evidence of restorations, gingival overgrowth, poorly defined gingival contour, impression and/or casting errors and fixed orthodontic appliances at any of the three examination periods were excluded from the study. However, the effects of mild poor oral hygiene and mouth breathing could not be evaluated by examining the study models alone. The retrospective design of the study, employing examination of study models, unfortunately did not allow for clinical evaluation. It was not possible to delineate which, if any of the children within the study group had received orthodontic treatment. Those with fixed appliances at any of the three examination periods were deliberately excluded from the study, as it was difficult to accurately record the crown height with an orthodontic bracket in situ and the possible effect on the gingival health could not be quantified accurately from study casts. However, it is possible that those treated with removable appliances, or short termed fixed appliances therapy worn between examination periods could have been included in the study sample. The specific effects of orthodontic treatment on the clinical crown length could not be assessed in this study.

Notwithstanding the limitations of the study method used, the present study has highlighted some of the issues surrounding passive eruption of teeth and the timing for placement of permanent anterior restoration in teenage and young adults. Subsequent to Shaw et al. completing the next phase of the study (age 28–29 years), there would be merit in extending the present investigation.

#### 5. Conclusion

The results of the present investigation indicate that the process of passive eruption, resulting in increased clinical crown length may be found to continue throughout the teenage years. Statistical analysis of the means for each age group for the maxillary right central incisor (11), maxillary right canine (13), maxillary left lateral incisor (22) and mandibular left central incisor (31) revealed significant ( $p < 0.0001$ ) increases in clinical crown length at each assessment period. The maxillary central incisor, lateral incisor and canine teeth results showed a 0.5 mm change in the clinical length the ages of 14–15 and 18–19 years. This finding is considered to be of importance to the clinician who is making treatment decisions for teenagers and young adults regarding the timing of restorative treatment which may approximate the gingivae in the anterior segment of the mouth.

## Acknowledgements

The authors express their gratitude to Prof. W. C. Shaw for the use of the casts used in this study.

## References

- [1] Shavell HM. The periodontal-restorative interface in fixed prosthodontics: Part 1. *Practical Periodontics and Aesthetic Dentistry* 1994;1:33–44.
- [2] Shavell HM. The periodontal-restorative interface in fixed prosthodontics: Part 11. *Practical Periodontics and Aesthetic Dentistry* 1994;6:49–60.
- [3] De-Waal H, Castellucci G. The importance of restorative margin placement to the biologic width and periodontal health: Part 1. *International Journal of Periodontics and Restorative Dentistry* 1993;13:461–71.
- [4] De-Waal H, Castellucci G. The importance of restorative margin placement to the biologic width and periodontal health: Part 11. *International Journal of Periodontics and Restorative Dentistry* 1994;14:70–83.
- [5] Dong JK, Jin TH, Cho HW, et al. The aesthetics of the smile: a review of some recent studies. *International Journal of Prosthodontics* 1999;12:9–19.
- [6] Okuda WH. Creating facial harmony with cosmetic dentistry. *Current Opinion in Cosmetic Dentistry* 1997;4:69–75.
- [7] Morley J. Smile design specific considerations. *Journal of the California Dental Association* 1997;9:633–7.
- [8] Gillen RF, Schwartz RS, Hilton TJ, et al. An analysis of selected normative tooth proportions. *International Journal of Prosthodontics* 1994;7:410–7.
- [9] Gargiulo AW, Wentz FM, Orban B. Dimensions and relations of the dentogingival junction in humans. *Journal of Periodontology* 1961;32:261–7.
- [10] Coslet JG, et al. Diagnosis and classification of delayed passive eruption of the dentogingival junction in the adult. *Alpha Omegan* 1977;3:24–28.
- [11] Dolt AH, Robbins JW. Altered passive eruption: an etiology of short clinical crowns. *Quintessence International* 1997;28:363–72.
- [12] Levine RA, McGuire M. The diagnosis and treatment of the gummy smile. *Compendium of Continuing Education in Dentistry* 1997;18:757–62.
- [13] Davis LG, Ashworth PD, Spriggs LS. Psychological effects of aesthetic dental treatment. *Journal of Dentistry* 1998;26:547–54.
- [14] Terry DA. Direct reconstruction of the maxillary anterior dentition with composite resin. *Practical Periodontics and Aesthetic Dentistry* 1999;11:361.
- [15] Rouse J, McGowan S. Restoration of the anterior maxilla with ultra-conservative veneers: clinical and laboratory considerations. *Practical Periodontics and Aesthetic Dentistry* 1999;11:333–9.
- [16] Bragger U, Lauchenauer D, Lang NP. Surgical lengthening of the clinical crown. *Journal of Clinical Periodontology* 1992;19:58–63.
- [17] Johnson RH. Lengthening clinical crowns. *Journal of the American Dental Association* 1990;121:473–6.
- [18] Volchansky A, Cleaton-Jones P. The position of the gingival margin as expressed by clinical crown height in children aged 6–16 years. *Journal of Dentistry* 1976;4:116–22.
- [19] Shaw WC, Addy M, Dummer PMH, et al. Dental and social effects of malocclusion and effectiveness of orthodontic treatment: a strategy for investigation. *Community Dentistry and Oral Epidemiology* 1986;14:60–64.